

ORIGINAL SCIENTIFIC PRESENTATION

Triceps Augmentation: Early Experience With the Procedure

Nikolas V. Chugay, DO; Paul N. Chugay, MD

In the past 10 years, there has been a noticeable increase in the number of men seeking cosmetic surgeons for enhancement of their physique, leading to the development of new and innovative techniques to meet their needs. According to the procedural census of the American Academy of Cosmetic Surgery (AACS) from 2002–2007, the total number of male patients treated by cosmetic surgeons has increased by 13.7%. Keeping this in mind, we have worked to develop a technique to advance physical enhancement in the upper extremity. Despite hard work at the gym and good dietary habits, some male patients are unable to attain the definition and shape to their upper extremities that they desire. In order to help men achieve a more sculpted upper extremity, we have worked to develop an implant and procedure to augment the triceps muscle. This procedure may be performed alone or in concert with a procedure to augment the biceps muscle.

Methods

A retrospective review of prospectively collected patient data was performed to identify appropriate study patients. Fourteen patients were identified as having undergone triceps augmentation with a custom-made solid silicone triceps prosthesis produced by AART Corp (Las Vegas, Nev).

Anatomic Considerations

The procedure of triceps augmentation is facile in that it avoids injury to the majority of vital structures in the upper limb. In our early experience with triceps augmentation, we began with a submuscular pocket for the implant. However, in our later cases we have

tended toward a subfascial plane of dissection, largely to provide the same definition to the muscle region without danger to vital anatomic structures.

The triceps muscle itself is a 3-headed muscle that is composed of 3 separate muscle bundles, each with separate origins and a common insertion at the olecranon. It is beneath the fascia of the long head of the triceps that the triceps implant is placed, to give more bulk or definition to the region (Figures 1 and 2).

Structures that may be encountered and therefore injured during the dissection of the pocket necessary for triceps augmentation are described below.

POSTERIOR CUTANEOUS NERVE OF THE ARM (POSTERIOR BRACHIAL CUTANEOUS NERVE)

This nerve is a branch of the radial nerve and provides sensory innervation for much of the skin on the back of the arm. This nerve is the upper arm

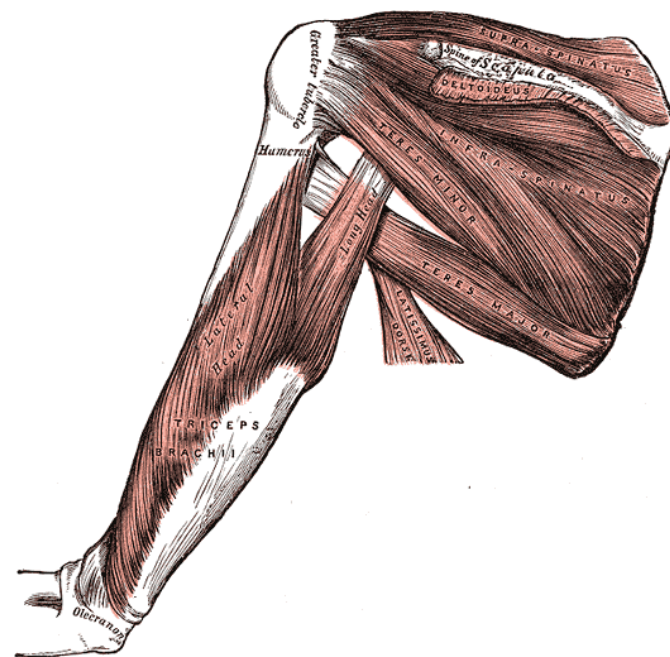


Figure 1. Illustration of the triceps muscle anatomically.¹

Received for publication December 24, 2009.
From the Chugay Cosmetic Surgery Institute, Long Beach, Calif.
Corresponding author: Nikolas V. Chugay, DO, 4210 Atlantic Ave,
Long Beach, CA 90807 (e-mail: docchugay@hotmail.com).

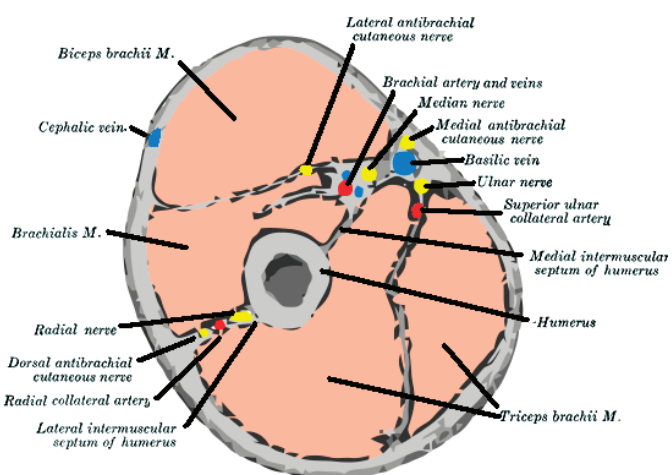


Figure 2. Cross section through middle of upper arm.

counterpart to the dorsal antebrachial cutaneous nerve, also a branch of the radial nerve that innervates the posterior aspect of the forearm. The posterior brachial cutaneous nerve arises in the axilla and passes through the axilla to the medial side of the arm supplying the skin on the dorsal aspect of the upper limb down to the level of the olecranon. This nerve may be encountered with over-dissection of the pocket, especially if one creates the pocket below the triceps muscle. If severed, the patient will complain of a lack of sensation to the posterior aspect of the upper arm. Excessive tension on the nerve may cause neurapraxia that is typically self-limited. It is for risk of injury to this nerve, that we favor a dissection of a pocket above the muscle in a subfascial plane.

ULNAR NERVE

The ulnar nerve comes from the medial cord of the brachial plexus and descends on the posteromedial aspect of the humerus. The nerve passes into the forearm and supplies motor function to the flexor carpi ulnaris and medial half of the flexor digitorum profundus. The nerve continues to the hand and supplies the hypothenar muscles, adductor pollicis, third and fourth lumbrical muscles, dorsal interossei and palmar interossei, and palmaris brevis. NOTE: This nerve should only be encountered in cases where the implant is placed below the triceps muscle rather than below the triceps fascia, and damage is typically due to tension on the nerve.

RADIAL NERVE

This nerve originates from the posterior cord of the brachial plexus and supplies the motor innervation to the posterior compartments of the arm and forearm,

which are primarily extensors of the upper limb. The nerve enters the arm behind the axillary artery and travels posteriorly on the lateral side of the arm. After giving off branches to the long and medial heads of the triceps, it enters the radial sulcus of the humerus. The nerve then travels in the groove between the medial and lateral heads of the triceps, coursing laterally on the posterior aspect of the humerus until it enters the anterior compartment of the arm in the mid upper arm. NOTE: This nerve should only be encountered in cases where the implant is placed below the triceps muscle rather than below the triceps fascia, and damage is typically due to tension on the nerve.

Surgical Procedure

The patient is brought to the operating room, prepped, and draped in the usual supine position. A 3- to 4-cm incision is made in the axillary region with a number 15 blade scalpel. The skin is elevated by sharp and blunt dissection with the operator's digit and Metzenbaum scissors. The fascia overlying the long head of the triceps muscle is identified. Next, an incision is made in the fascia with a number 15 blade scalpel in the direction of the muscle fibers. Stay sutures are then placed into the muscle fascia to aid in closure at the end of the procedure. The long head of the triceps is then visualized. Blunt dissection is performed using the operator's digit underneath the fascia overlying the long head of the triceps muscle. Once the pocket dissection is well underway, a spatula dissector is placed underneath the fascia, and the dissection of the pocket is completed. The plane of dissection is continued distally toward the elbow. A custom-made, solid silicone triceps prosthesis is placed underneath the fascia of the long head of the triceps muscle. Once the position of the implant is deemed satisfactory, closure in layers is begun. The fascia is repaired with 3-0 Vicryl suture. The subcutaneous tissues are then reapproximated using 4-0 Vicryl suture. The skin is then closed in subcuticular fashion using 4-0 Monocryl suture.

The patients are sent home with explicit directions for postoperative activity and wound care. On discharge, the patients have their arms wrapped in elastic compression sleeves to diminish the amount of swelling and potential for seroma formation. These sleeves are to be worn at all times for a period of 2 weeks. Also, the patients are asked to avoid heavy lifting and strenuous activity for 1 month. They

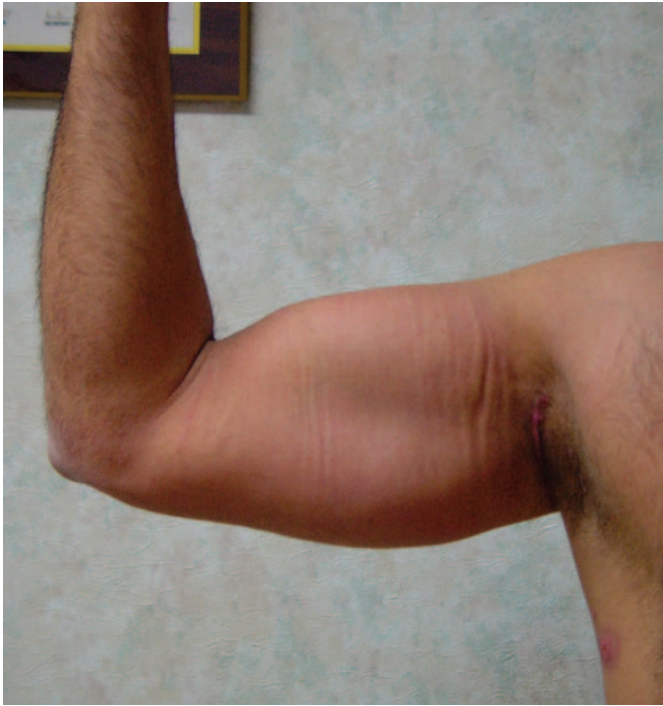

Figure 3. Preoperative photograph of the right triceps— anterior view.

are allowed to shower within 3 days of the surgery, keeping the operative site clean with peroxide and bacitracin. Beginning on postoperative day 4, the patients are asked to begin painting the incision with Betadine twice daily until seen in follow-up.

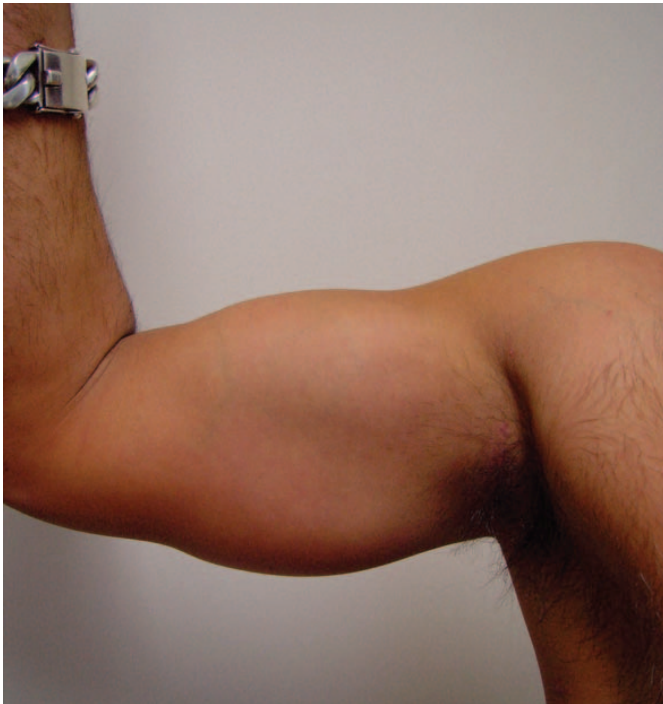

Figure 4. Postoperative photograph of the right triceps— anterior view.

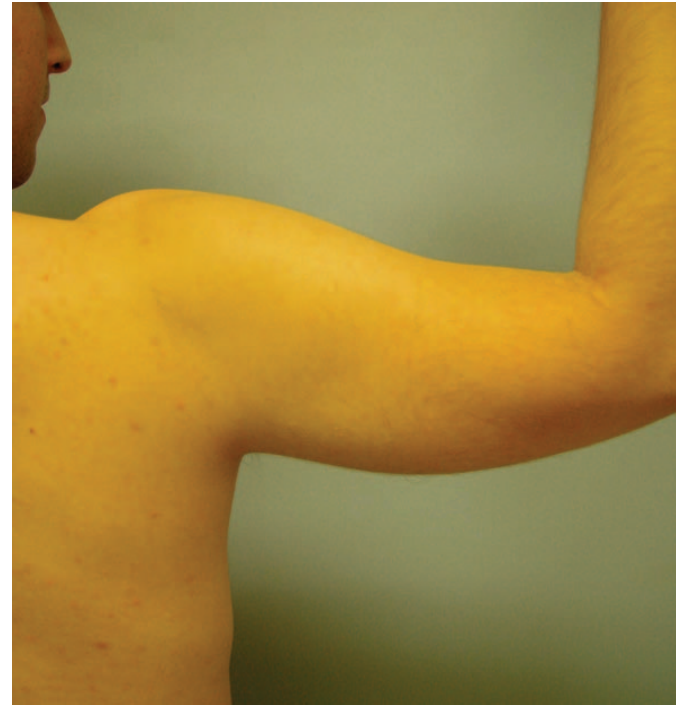

Figure 5. Preoperative photograph of the right triceps— posterior view.

Results

Fourteen cases of triceps augmentation have been performed over the past 2 years. The potential complications of the procedure include infection, seroma development, bleeding, implant extrusion,

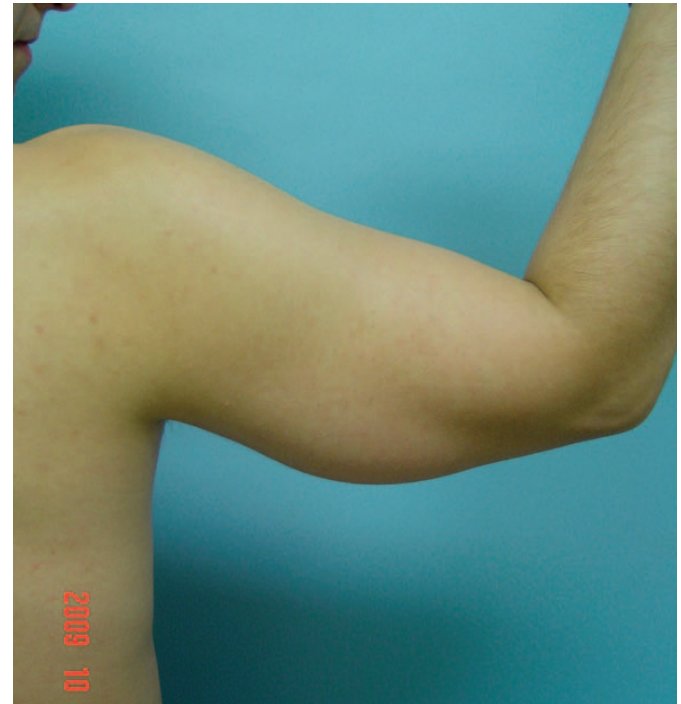

Figure 6. Postoperative photograph of the right triceps— posterior view.

asymmetry, scarring, muscle damage, nerve damage, and malposition of the implant. In the 14 cases performed, there were 3 complications: 1 case of neurapraxia and 2 cases of implant migration.

The first complication was a patient report of weakness in the hand on the operative side with noticeable difficulty in writing. This patient did not desire corrective surgery and had spontaneous resolution of his weakness. Admittedly, this was one of the first patients who underwent triceps augmentation, and the dissection performed was more aggressive than is currently our practice. This may have put unnecessary tension on the ulnar nerve resulting in neurapraxia in the distal distribution of the nerve, affecting the muscles of the hand. In this patient, the prosthesis was placed in a submuscular plane beneath the long head of the triceps muscle. It is now our practice to perform subfascial placement of the prosthesis to prevent excessive dissection, decrease the incidence of bleeding complications, and decrease the incidence of neurapraxia due to nerve injury.

The other 2 complications were extrusions of the prosthesis from below the fascia. These were corrected by a return to the operating room for tacking of the fascia to the triceps muscle to prevent future migration.

To avoid implant migration, our practice now is to tack the fascia of the triceps muscle down to the muscle to create a snug fit around the implant (Figures 3 through 6).

Conclusions


Although relatively new, triceps augmentation is another tool available to the cosmetic surgeon to aid in providing patients with their desired physique. The operation is a relatively straightforward procedure that affords great results. Prudent dissection of the pocket and meticulous closure at the end of the procedure are essential to attaining optimal cosmesis and preventing implant migration. Most of the dissection performed during the procedure is blunt with natural tissue planes, thus preventing any damage to vital structures in the upper arm.

References

1. Gray H. *Anatomy of the Human Body*. Philadelphia, Pa: Lea & Febiger; 1918.
2. Chugay N, Chugay P. Bicipital augmentation. *Am J Cosmet Surg*. 2006;23(1):33–36.

Introducing

The Niamtu Cosmetic Facial Surgery Instructional DVD Series Volume 1



Dr. Joe Niamtu is well known in international cosmetic surgery circles as a surgeon, author and lecturer. He has documented the most contemporary cosmetic facial surgery procedures in high definition 1080p DVD video. This video series will serve as an excellent teaching tool for the novice surgeon and great review for experienced surgeons.

Learn more at our website:
www.CosmeticSurgeryEducation.com

— DVD TITLES AVAILABLE INCLUDE: —

Injectable Fillers • Neurotoxins • Blepharoplasty
Brow & Forehead Lift • Face & Neck Lift
Minimally Invasive Facelift • Facial Implants • Otoplasty
Laser Skin Resurfacing • Chemical Face Peel
"Scarless" Mole Removal • Surgical Lip Enhancement

